CanaDent

The A, B, C of

Endodontic Practice

2 Day Course Webinar

May 1st (Saturday)

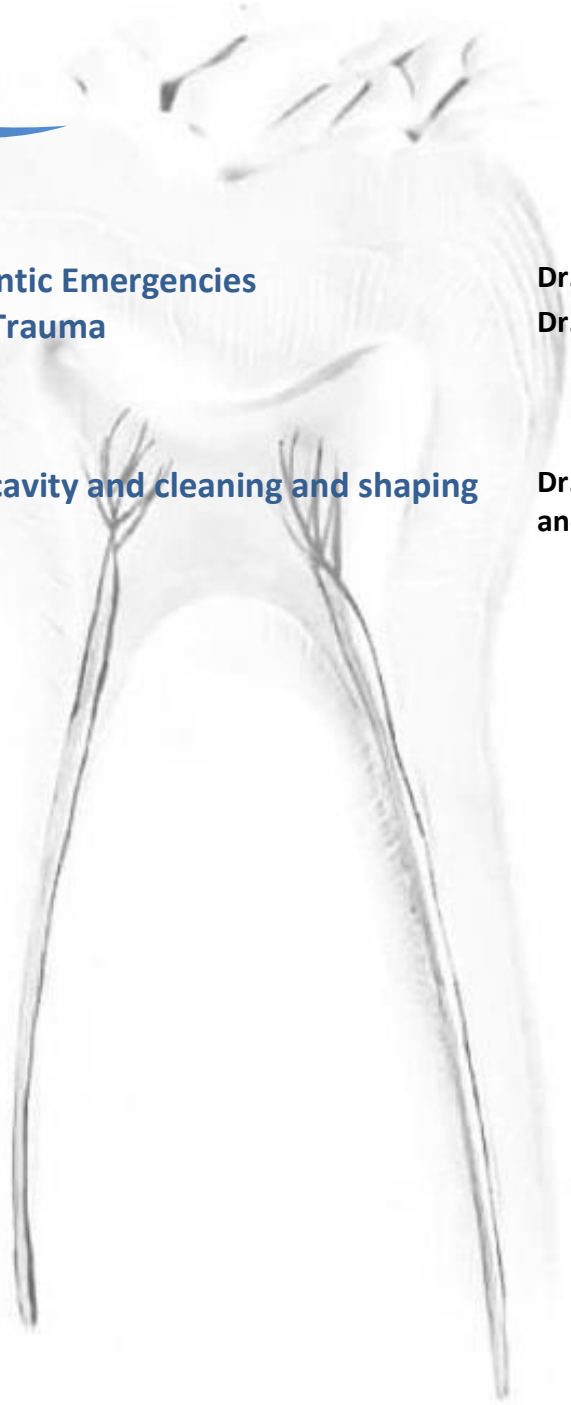

09:00 - 11:30 AM	Endodontic Emergencies Dental Trauma	Dr. Shahrokh Shabahang Dr. Avina Paranjpe
11:30 - 12:00 PM	Q/A	
12:30 – 03:00 PM	Access cavity and cleaning and shaping	Dr. Mahmoud Torabinejad and Ove Peters
03:00 - 03:30 PM	Q/A	

CanaDent

May 9th (Sunday)

09:00 - 11: 30 AM	Obturation Techniques	Mahmoud Torabinejad and Mohammad Sabeti
11:30 – 12:00 PM	Q/A	
12:30 – 03:00 PM	Restoration of Endo treated teeth	Dr. Charles Goodacre
03:00 - 03:30 PM	Q/A	

CanaDent

• Endodontic Emergencies

Shahrokh Shabahang, DDS, MS, PHD

Associate Professor, Department of Endodontics, School of Dentistry, Loma Linda University, Loma Linda, Ca, USA

Abstract

Emergency need for dental care may arise from pathoses related to dental and surrounding tissues and must be distinguished from a patient's desire to be seen urgently. Typically, conditions that require urgent appointments include severe pain and/or infection. Using a set of probing questions, the receptionist can differentiate between these two categories. Once the determination has been made to see a patient on an emergency basis, care must be taken to obtain complete information about the history of the condition, relevant medical history as well as data from clinical and radiographic examinations. As tempting as it is to want to help a patient with pain or infection, above all, a prudent clinician must do no harm. No treatment is better than rendering the wrong treatment and to avoid mistakes; an accurate diagnosis is required before providing any treatment.

OBJECTIVES

1. Knowing when a patient needs to be seen urgently
2. Proper collection of data
3. Steps to arrive at correct diagnosis
4. Best options for managing endodontic emergencies
5. Selection and use of medications, including analgesics and antibiotics, in endodontic emergencies

- ## Dental Trauma

Avina Paranjpe, BDS, MS, MSD, PHD

Associate Professor, Department of Endodontics, University of Washington, Seattle, WA, USA

Abstract

Dental emergencies primarily consist of pulpal and periapical inflammation and trauma. Dental trauma can occur in children as well as in adults and constitutes about 5 % of all injuries. The most commonly occurring traumatic injuries in children are luxation injuries and those in the adult population are crown fractures. As a healthcare provider it is necessary to be able to recognize these injuries and treat them adequately and appropriately to ensure a successful outcome. This presentation will focus on the types of trauma, ways to recognize them, treatment modalities and differences in treatment between a mature versus an immature tooth.

OBJECTIVES

1. Classify dental traumatic injuries.
2. Diagnostic modalities for dental trauma
3. Treatment modalities for the various types of traumatic injuries and their possible complications.

- ## Access cavity and cleaning and shaping

Mahmoud Torabinejad, DMD, MSD, PHD

Affiliate Professor of Endodontics, Department of Endodontics, University of Washington Seattle, WA, USA

Adjunct Professor, Department of Endodontics, School of Dentistry, Loma Linda University, Loma Linda, CA, USA

Adjunct Professor, Department of Endodontics, University of Pacific Arthur A. Dugoni School of Dentistry

Adjunct Professor, Department of Preventive and Restorative Dentistry, Section of Endodontics, University of California in San Francisco, School of Dentistry, San Francisco, CA, USA

Ove A. Peters, DMD, MS, PHD

Professor and Discipline Lead, Endodontics, School of Dentistry, The University Of Queensland, Brisbane, Qld, Australia

Abstract

During root canal treatment, clinicians use a combination of hand- and engine-driven instrument with the overall goal of forming and debriding the root canal system. A variety of principles have been established to ensure that clinical procedures are met with successful outcomes. This presentation with provide both a brief overview of principles and recommendations for contemporary practice.

According to well-established principles, the final canal shape should be a tapered funnel that incorporates the original canal path and does not change the apical foramen in location and size. This accomplished more easily in straight compared to curved canals. Specific instrument sequences and strategies such as early coronal modification is more appropriate for curved canals and adapted to the use of rotary / reciprocating instruments. Examples for specific instrument designs and fabrication techniques will also be discussed, as they are relevant for clinical handling. Evidence for specific step and principle will be provided.

OBJECTIVES

It is anticipated that clinicians, after attending this presentation, will be able to:

1. describe objectives for biomechanical cleaning and shaping and explain how to determine when these have been achieved.
2. discuss techniques for shaping canals that are regular or irregular in shape
3. apply evidence-based principles for instrument handling in their clinical practices

- ## Obturation Techniques

Mahmoud Torabinejad, DMD, MSD, PHD

Affiliate Professor of Endodontics, Department of Endodontics, University of Washington Seattle, WA, USA

Adjunct Professor, Department of Endodontics, School of Dentistry, Loma Linda University, Loma Linda, CA, USA

Adjunct Professor, Department of Endodontics, University of Pacific Arthur A. Dugoni School of Dentistry

Adjunct Professor, Department of Preventive and Restorative Dentistry, Section of Endodontics, University of California in San Francisco, School of Dentistry, San Francisco, CA, USA

Mohammad Sabeti, DDS, MA

Clinical Professor, PRDS, University of California at San Francisco, San Francisco, CA, USA

Abstract

Success in endodontic therapy is dependent on adequate instrumentation, disinfection, and obturation of the root canal system. The objective of obturation is to create a watertight seal along the length of the root canal system from the orifice to the apical termination. Obturation prevents leakage of microorganisms and their byproducts into the root canal system from a coronal direction and leakage of periapical tissue fluids into the root canal system from an apical direction. A periapical lesion may heal at least temporarily after root canal debridement without obturation (2). The presenters will review the goals of the obturation, when to obturate, removal of smear layer, obturation materials, obturation techniques, and future directions in obturation techniques and materials.

Objectives:

1. Explain the objectives of root canal obturation.
2. Explain the rationale for smear layer removal.
3. List the ideal properties of an obturation material.
4. Identify obturation materials
5. Explain how to perform different obturation techniques

Restoration of Endo treated teeth

Charles J. Goodacre, DDS, MSD

Distinguished Professor, Department od Restorative Dentistry, School of Dentistry, Loma Linda University, Loma Linda, CA, USA

Abstract

Endodontic therapy is predictable. However, for success the teeth need to be restored to their previous form and function. Prior to endodontic therapy, restorability must be determined; this involves careful evaluation of the existing tooth structure, including removal of all caries along with any existing restorations, both to reduce the risk of marginal leakage during treatment[1] and to reveal the amount of sound tooth structure. Specific restorative options must be evaluated based on functional demand and remaining tooth structure. This presentation will provide answers to the most frequently asked questions regarding the restoration of endodontically treated teeth considering the contemporary evidence and clinical practice.

Objectives:

1. Determine which endodontically treated teeth need crowns.
2. Describe the effect of post and cores upon endodontically treated teeth.
3. Identify the design characteristics and clinical procedures that create optimal success when restoring root canal treated teeth with posts and cores.

CanaDent

www.canadent.net/registeration

+1 (647) 615 3333